

Received: 2017.04.05  
Accepted: 2017.06.12  
Published: 2017.10.20

ISSN 1941-5923  
© Am J Case Rep, 2017; 18: 1123-1125  
DOI: 10.12659/AJCR.904693

## Foreign Body Ingestion Causing Recurrent Diverticulitis

Authors' Contribution:  
Study Design A  
Data Collection B  
Statistical Analysis C  
Data Interpretation D  
Manuscript Preparation E  
Literature Search F  
Funds Collection G

ABCDEF 1 **Gregory N. Nicolas**  
BDEFG 2 **Richard Assaker**  
AEFG 1 **Christian Saliba**  
EG 1 **Dani R. Osman**  
BDEF 3 **Elliot Khoury**  
CDE 4 **Maguy Abdellah Farhat**  
CDEG 3 **Riad R. Azar**  
DFG 1 **George Khoury**

1 Department of Surgery, Lebanese American University Medical Center  
– Rizk Hospital, Beirut, Lebanon  
2 Department of Radiology, Lebanese American University Medical Center  
– Rizk Hospital, Beirut, Lebanon  
3 Department of Gastroenterology, Lebanese American University Medical  
Center – Rizk Hospital, Beirut, Lebanon  
4 Department of Internal Medicine, Lebanese American University Medical Center  
– Rizk Hospital, Beirut, Lebanon

**Corresponding Author:** Gregory Nicolas, e-mail: [gregory.nicolas@lau.edu](mailto:gregory.nicolas@lau.edu)  
**Conflict of interest:** None declared

**Patient:** **Male, 73**  
**Final Diagnosis:** **Foreign body causing recurrent diverticulitis**  
**Symptoms:** **Chronic abdominal pain**  
**Medication:** —  
**Clinical Procedure:** —  
**Specialty:** **Gastroenterology and Hepatology**

**Objective:** **Challenging differential diagnosis**

**Background:** Ingested foreign bodies (IFBs) are usually asymptomatic and are excreted uneventfully. IFBs become a major concern in elderly patients due to the increase number of diverticuloses where the foreign body can lodge and cause severe complications.

**Case Report:** We report a case of an elderly patient who ingested a chicken bone that caused recurrent diverticulitis.

**Conclusions:** The diagnosis of complicated IFB cases is challenging, requires physician clinical expertise, and must be considered in individuals at risk.

**MeSH Keywords:** **Colonoscopes • Foreign Bodies • Sigmoid Diseases**

**Full-text PDF:** <https://www.amjcaserep.com/abstract/index/idArt/904693>



1021



—



1



9



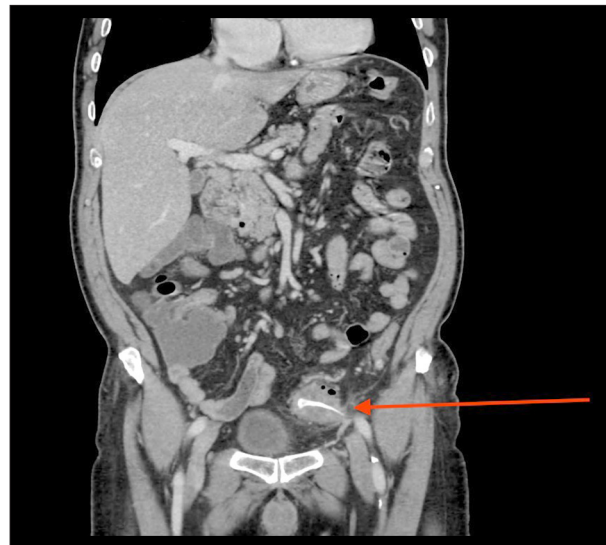
## Background

Diverticulitis is one of the most common etiologies responsible for bowel emergencies in patients presenting with the non-specific symptoms of acute abdomen [1]. It is considered a part of the clinical and pathological spectrum of diverticular diseases [2]. It is defined as microperforation and inflammation of the peridiverticular wall, which develops due to increased pressure at the diverticular ostium, usually as a result of an obstructing fecalith. Typically, affected patients are diagnosed by computed tomography, which is considered the criterion standard for diagnosis as well as for assessment of the degree of severity. Uncomplicated cases are usually managed conservatively by bowel rest and antibiotics. However, patients presenting with complicated disease such as perforation, phlegmon, abscess, or fistulas, require more aggressive management, which includes surgical intervention to avoid life-threatening situations [3]. Moreover, this case highlights an entity of special importance – a foreign body-induced diverticulitis – which has been documented in the literature. There are documented cases of recurrent diverticulitis refractory to conservative management, which were later found to be triggered by foreign bodies that were not initially detected on imaging. This case highlights the importance of foreign body-induced diverticulitis, especially in the elderly, in whom a predisposing diverticulosis has a prevalence of 50% [4].

## Case Report

A 73-year-old man with a past history of hypertension was admitted for a 1-year history of recurrent left lower quadrant pain. Twelve months before, the patient suddenly began experiencing abdominal pain in the left lower quadrant, which was burning, intermittent, and severe (scale 7–9/10), sometimes lasting several hours at a time. In addition, the pain was non-radiating, mildly relieved with NSAID, and exacerbated by food intake. He had been admitted multiple times to several different hospitals with similar symptoms, leukocytosis, and elevated CRP. Abdominal CT scans had been repeated several times during these admissions, showing evidence of acute sigmoid colon diverticulitis. He was discharged on several of these occasions on a 1-week course of ciprofloxacin and metronidazole, but had recurrence of symptoms, leading to readmission.

His most recent admission was to our hospital on 03/01/2017 for a recurrence of abdominal pain that had lasted 2 weeks. Lab test results again showed leukocytosis and elevated CRP. The patient was prepared for colonoscopy due to suspicion of malignancy, which showed multiple diverticulae in the sigmoid and in an area of relative narrowing with impacted food seen in the mid-sigmoid. An abdominal CT scan with IV



**Figure 1.** Contrast-enhanced CT abdomen with coronal reconstruction showing the ingested foreign body as a bony attenuation in the sigmoid colon with the tip projecting beyond the bowel wall, and surrounding fat stranding suggesting inflammatory changes.

contrast was performed, showing an intraluminal, linear, foreign body (Figure 1). The foreign body demonstrated a bony attenuation with a pointed tip transfixing the sigmoid wall at this level, with the tip seen outside of the lumen. It was surrounded by fat stranding and reactive inflammatory changes, as well as thickening of the sigmoid wall. A mild amount of fat stranding was also noted surrounding the sigmoid colon and extending to the urinary bladder wall, which appeared mildly thickened with shaggy borders. Multiple subcentimeter lymph nodes were also noted, with no evidence of diverticulitis on the exam. There was no evidence of an abscess, collection, or free fluid within the abdomen and pelvis.

Colonoscopy was later repeated with better preparation, showing multiple diverticulae in the sigmoid colon. An area of relative narrowing was also seen within the mid-sigmoid. The foreign body, however, was not visible on this exam, suggesting that the bone had migrated since the previous colonoscopy and additional preparation. A repeat CT abdomen was done following the second colonoscopy, which showed complete absence of the previously visible foreign body.

The patient was discharged on 1 week of antibiotics and regular diet, and has since remained symptom-free with no complaints.

## Discussion

Several cases of ingested foreign body (IFB) have been described in the literature, mostly occurring in alcoholic patients,

the elderly (especially those who wear dentures), and those with psychiatric disorders.

Most commonly, IFB are food particles, such as fish bones, chicken bones, or food fragments. Fortunately, most food particles pass uneventfully. However, there are bony fragments that may lead to abdominal complications such as diverticulitis, GI perforation, and abscess formation. Gossypiboma, a surgical complication resulting from foreign materials left in the patient during the operation, was not the case in this patient because there had been no recent surgery or any complication post-surgery [5].

Glasson et al. [6] reported a case with perforated sigmoid diverticulum caused by a chicken bone. Akhtar et al. [7] reported 3 cases with bowel perforation caused by chicken bones: 2 cases with a preceding hernia and the other with a preceding diverticulitis.

Most IFB cases are asymptomatic and are often found incidentally on abdominal imaging. When symptomatic, the most common clinical findings are abdominal pain and fever.

These cases are very difficult to diagnose since the patient is unlikely to recall ingestion of the food particle.

What is interesting about this particular case is that the symptoms of diverticulitis had been recurring for the past 8 months without diagnosis of an underlying cause. This is an example of the need for high clinical suspicion, especially in the elderly,

## References:

1. Sebbane M, Dumont R, Jreige R, Eledjam JJ: Epidemiology of acute abdominal pain in adults in the Emergency Department setting. In: Taourel P (ed.), *CT of the Acute Abdomen*. Medical Radiology. Berlin: Springer Verlag, 2011; 3–13
2. Boynton W, Floch M: New strategies for the management of diverticular disease: Insights for the clinician. *Therap Adv Gastroenterol*, 2013; 6(3): 205–13
3. Onur MR, Akpınar E, Karaosmanoglu AD et al: Diverticulitis: A comprehensive review with usual and unusual complications. *Insights Imaging*, 2017; 8(1): 19–27
4. Huyskens J, Van Hedent E, Trappeniers L et al: Gastrointestinal complications of accidental ingestion of foreign objects. *JBR-BTR*, 2015; 98(1): 27–31
5. Ratnani R: Gossypiboma mimicking as ovarian tumor – a rare case report. *Obstet Gynecol Int J*, 2016; 5(2): 00145
6. Glasson R, Haghighi KS, Richardson G: Chicken bone perforation of a sigmoid diverticulum. *ANZ J Surg*, 2002; 72(6): 448–49
7. Akhtar S, McElvanna N, Gardiner KR, Irwin ST: Bowel perforation caused by swallowed chicken bones – a case series. *Ulster Med J*, 2007; 76(1): 37–38
8. Näf F, Choschick M, Melcher GA: Atypical case of a painful presacral tumor. *Am J Case Rep*, 2015; 16: 760–62
9. Emir S, Ozkan Z, Altınsoy HB et al: Ingested bone fragment in the bowel: Two cases and a review of the literature. *World J Clin Cases*, 2013; 1(7): 212–16

and appropriate imaging modalities in the diagnosis of symptomatic ingestion of foreign bodies. Abdominal X-ray has limited sensitivity in detecting fish or chicken bones because these particles are less radiopaque. The most useful imaging modality in detecting these particles is an abdominal CT scan, which will reveal the bony lesion at the site of inflammation. On CT scan, we were able to rule out presacral tumor, a tumor developed due to a surgical complication when a foreign object is left inside the body during the operation [8].

Some of these foreign objects will pass on their own; however, Seyfi et al. [9] reported that 1% of complicated IFB cases required surgical operation, whereas 10–20% of bony particles (especially at the anorectal region) were removed via proctosigmoidoscopy and endoscopy.

## Conclusions

We report the case of a man with an IFB that caused an abdominal complication, recurrent diverticulitis, which mimicked an acute abdomen. Physicians should have the clinical expertise to ask for the optimal medical imaging, which consists of a CT abdomen that will detect the bony lesion before any invasive procedure is performed.

## Conflicts of interest

None.