



Julie Gilbert Pollard. *Box Canyon*. Oil on canvas, 18" × 24".

*Therapeutic options for neoplastic meningitis include systemic therapy, the intra-CSF administration of chemotherapy, and CNS site-specific radiotherapy.*

## Neoplastic Meningitis Due to Lung, Breast, and Melanoma Metastases

Emilie Le Rhun, MD, Sophie Taillibert, MD, and Marc C. Chamberlain, MD

**Background:** Neoplastic meningitis, a central nervous system (CNS) complication of cancer metastatic to the meninges and cerebrospinal fluid (CSF), is relevant to oncologists due to the impact of the disease on patient quality of life and survival rates.

**Methods:** A review of the literature of articles published in English was conducted with regard to neoplastic meningitis.

**Results:** The incidence of neoplastic meningitis is increasing because patients with cancer are surviving longer in part because of the use of novel therapies with poor CNS penetration. Up to 5% of patients with solid tumors develop neoplastic meningitis during the disease course (breast cancer, lung cancer, and melanoma being the predominantly causative cancers). The rate of median survival in patients with untreated neoplastic meningitis is 1 to 2 months, although it can be as long as 5 months in some cases. Therapeutic options for the treatment of neoplastic meningitis include systemic therapy (cancer-specific, CNS-penetrating chemotherapy or targeted therapies), intra-CSF administration of chemotherapy (methotrexate, cytarabine, thiotepa) and CNS site-specific radiotherapy. Determining whom to treat with neoplastic meningitis remains challenging and, in part, relates to the extent of systemic disease, the neurological burden of disease, the available systemic therapies, and estimated rates of survival.

**Conclusions:** The prognosis of neoplastic meningitis remains poor. The increasing use of novel, targeted therapies and immunotherapy in solid tumors and its impact on neoplastic meningitis remains to be determined and is an area of active research. Thus, well conducted trials are needed.

### Introduction

Neoplastic meningitis, also known as leptomeningeal metastasis or carcinomatous meningitis, reflects the metastatic infiltration of the cerebrospinal fluid (CSF) and leptomeninges (pia and arachnoid) by can-

cer. Neoplastic meningitis is the third most common cause of central nervous system (CNS) metastases after brain metastases and epidural spinal cord compression.<sup>1</sup> The diagnosis and treatment of neoplastic meningitis are of clinical relevance due to their im-

*From the Division of Neuro-Oncology (ELR) in the Department of Neurosurgery, University Hospital, the Breast Unit (ELR) in the Department of Medical Oncology, Oscar Lambret Center, Lille Cedex, France, the Division of Neuro-Oncology (ST) in the Departments of Neurology and Radiation Oncology, Pitié-Salpêtrière Hospital, Assistance Publique des Hôpitaux de Paris, Université Pierre et Marie Curie, Paris, France, and the Department of Neurology (MCC), Fred Hutchinson Cancer Research Center, (MCC), Seattle Cancer Care Alliance (MCC), and Division of Neuro-Oncology (MCC), Departments of Neurology and Neurological Surgery, University of Washington School of Medicine, Seattle, Washington.*

*Submitted July 29, 2015; accepted December 9, 2015.*

*Address correspondence to Marc C. Chamberlain, MD, Seattle Cancer Care Alliance, 825 Eastlake Avenue East, Post Office Box 19023, MS G4940, Seattle, WA 98109. E-mail: marcccchamberlain@gmail.com*

*Dr Le Rhun has received funding for research from Amgen and Mundipharma. Dr Taillibert has received funding for research from Mundipharma. Dr Chamberlain has received funding for research, is a consultant for, and holds stock in Pharmaco-Kinesis, Nativis, Roche, and Tocagen.*

pact on patient quality of life and rate of survival.

The incidence of neoplastic meningitis is increasing due in part to improved rates of survival, because more effective systemic agents with poor CNS penetration are being used.<sup>2,3</sup> Up to 5% of patients with solid tumors will develop neoplastic meningitis during the course of their disease.<sup>4</sup> The incidence of undiagnosed neoplastic meningitis may be 40% or more in solid tumors.<sup>5</sup>

Among solid tumors, breast cancer (12%–35% of all cases of neoplastic meningitis), lung cancer (10%–26%), and melanoma (5%–25%) represent the most common causative cancers that result in neoplastic meningitis.<sup>4,6–9</sup> Due to its high incidence, breast cancer is the most common cause of solid tumor–related neoplastic meningitis, with an estimated occurrence of 3% to 5%.<sup>4</sup> The incidence of neoplastic meningitis in non–small-cell lung cancer (NSCLC) is approximately 1% to 3%.<sup>4,7</sup> Neoplastic meningitis may be observed in up to 20% of patients with metastatic melanoma.<sup>4,7</sup> Neoplastic meningitis is diagnosed in most patients (70% overall) with active systemic disease; however, neoplastic meningitis can present as the first site of metastatic disease after a disease-free interval (20%) or may be the first manifestation of cancer (5%).<sup>4,8</sup>

## Physiopathology

Tumor cells invade the leptomeninges and CSF by various means, including via hematogenous spread (either through arterial dissemination or through the Batson venous plexus), endoneural/perineural or perivascular lymphatic spread, and direct extension from the brain parenchyma or choroid plexus. Primary leptomeningeal tumors may be also observed, particularly with melanoma.<sup>9</sup>

After entering the subarachnoid space, cancer cells disseminate through the neuraxis via the dynamic flow of the CSF and metastasize to multiple sites in the CNS.<sup>4</sup> Tumor cell infiltration of the CSF predominates at the base of the brain, the dorsal spinal cord, and the cauda equina.<sup>8</sup> Two pathological patterns of neoplastic meningitis can be distinguished and are often related: (1) subarachnoid or intraventricular nodular disease, and (2) nonadherent malignant cells suspended and circulating in CSF (ie, circulating tumor cells [CTCs]).<sup>6</sup>

## Risk Factors

Several studies have reported a higher incidence of neoplastic meningitis after surgical resection for brain metastases compared with primary treatment (radiotherapy).<sup>10,11</sup> Thus, surgical resection, particularly of cerebellar brain metastasis, may increase the risk of developing neoplastic meningitis. In addition, when supratentorial brain metastasis is resected

and a ventricle is entered, this appears to increase the risk of CSF dissemination.<sup>11,12</sup> An increased incidence of neoplastic meningitis has also been reported after piecemeal resection vs en bloc resection of brain metastasis.<sup>10</sup>

In the infiltrative lobular subtype of breast cancer, negative *ER* and negative *PR* tumors are associated with an increased risk of neoplastic meningitis.<sup>7,13,14</sup> Triple-negative status (ie, *ERBB2* [formerly known as *HER2/neu*] negative, *ER* negative, and *PR* negative) may be a risk factor, although *ERBB2* has not yet been identified as a risk factor for neoplastic meningitis.

In NSCLC, adenocarcinoma histopathology has been implicated as a risk factor for the development of neoplastic meningitis.<sup>15,16</sup> *EGFR* or *ALK* mutations in NSCLC may be risk factors of neoplastic meningitis, although this supposition has not been clearly established.<sup>17</sup> Few case series of melanoma-associated neoplastic meningitis have been reported, and no risk factors have yet to be identified.<sup>18–20</sup>

## Diagnosis

According to guidelines published by the National Comprehensive Cancer Network (NCCN), the diagnosis of neoplastic meningitis may be determined by the presence of CTCs in the CSF.<sup>21</sup> In the absence of CTCs in the CSF, neoplastic meningitis has been defined as the presence of neuroradiological findings consistent with neoplastic meningitis and associated with characteristic symptoms and signs of neoplastic meningitis in the setting of cancer.<sup>4,7,21</sup> A diagnosis of probable neoplastic meningitis can also be made in those with cancer who present with symptoms and signs consistent with neoplastic meningitis, CSF abnormalities (although nonspecific), and inconclusive findings on magnetic resonance imaging (MRI).<sup>1</sup> Underdiagnosis remains a challenge because establishing a diagnosis of neoplastic meningitis requires specific assessments (analysis of CSF and imaging of the CNS) based on a clinical suspicion of neoplastic meningitis; those challenges notwithstanding, corroborative test results may also be normal.<sup>7</sup>

## Clinical Symptoms and Signs

Patients with neoplastic meningitis frequently present with multifocal neurological symptoms and signs related to specific domains of the CNS involved with CTCs. Clinical manifestations may have a subtle presentation in some patients. Neurological symptoms and signs are classically categorized as belonging to 1 of 3 CNS domains: (1) cerebral hemispheres, (2) cranial nerves, and (3) spinal cord/nerve roots.<sup>3,22</sup> Shown in Table 1, the most frequent manifestations of neoplastic meningitis are headache, change in mental status, gait abnormality, vomiting (cerebral

**Table 1. — Symptoms and Signs of Neoplastic Meningitis at Diagnosis**

Location	Symptom	Incidence, %	Sign	Incidence, %
Cerebral hemisphere	Headache	51–75	Mental status change	27–65
	Mental change	26–33	Seizure	11–18
	Gait difficulty	27	Focal/generalized	11/6
	Nausea and vomiting	22–34	Papilledema	11
	Unconsciousness	4	Sensory disturbance	11
	Dysphagia	4	Diabetes insipidus	4
	Coordination disorders	20–34	Hemiparesis	2
	Loss of consciousness	4	Cerebellar disorder	15
Cranial nerve	Diplopia	20–36	Ocular motor paresis (III, IV, VI)	5–36
	Visual loss	9–10	Facial paresis (VII)	10–27
	Hearing loss	5–14	Visual loss (II)	5–19
	Decreased hearing	5	Optic neuropathy	8
	Tinnitus	3	Reduced hearing (VIII)	7–18
	Facial numbness	8–10	Trigeminal neuropathy (V)	6–10
	Hypogeusia	4	Reduced gag reflex (IX, X)	2–6
	Dysphonia/dysphagia	2–7	Hypoglossal neuropathy (XII)	5–10
	Hoarseness	3		
	Vertigo	2		
Spinal cord/nerve roots	Lower motor neuron weakness	34–46	Reflex asymmetry	86
	Paresthesia	33–42	Nuchal rigidity	9–13
	Pain		Weakness	73
	Back/neck	31–37	Sensory loss	32
	Radicular	26–37	Straight leg raising	15
	Bladder and bowel dysfunction	16–18	Decreased rectal tonus	5–14
	Upper motor neuron weakness	14		

Data from references 23 to 28.

hemisphere dysfunction), diplopia and facial paresis (cranial nerve involvement), lower extremity weakness and paresthesias, back or neck pain, and radiculopathy (spinal cord/exiting nerve-root manifestations).<sup>23–28</sup> Clinical manifestations suggestive of neoplastic meningitis are the development of cauda equina syndrome, communicating hydrocephalus, or cranial neuropathy.<sup>1</sup> Typically, neurological signs exceed the number of symptoms, so a careful neurological examination is required to assist in the diagnosis and management of neoplastic meningitis.<sup>4,29</sup> Meningismus (neck stiffness) is uncommon and presents in fewer than 15% of cases.<sup>23–28,30</sup> Headache, nausea, and vomiting due to raised intracranial pressure are frequent. Seizures are uncommon and occur in fewer than 10% of patients.<sup>30</sup>

Clinical manifestations may overlap with those

of concomitant brain metastasis, treatment-related toxicity, metabolic disturbances, other causes of chronic meningitis (tuberculosis, fungal infections, sarcoidosis), or — rarely — paraneoplastic syndromes.<sup>1,7,8</sup> However, the presentation differs from that of infectious or hemorrhagic meningitis, because fever, meningismus, and photophobia are rare in this patient population.<sup>4,7</sup> Concomitant primary or secondary brain cancer may amplify the neurological manifestations of neoplastic meningitis.

### Imaging Assessment

MRI with contrast of the brain and spinal cord is the imaging modality of choice for the radiographical evaluation of neoplastic meningitis.<sup>4,6,7</sup> Contrast-enhanced, T1-weighted imaging and sequences of fluid attenuation inversion recovery are the most sensitive for detecting neoplastic meningitis.<sup>4,7</sup> At diagnosis, brain involvement can be observed in 40% to 75% of patients and spinal involvement can be seen in 15% to 25%.<sup>7</sup> Findings on MRI can include focal or diffuse pial enhancement; ependy-

mal, sulcal, folia, or cranial nerve enhancement; and subarachnoid, ventricular, or parenchymal-enhancing nodules. Hydrocephalus, which is a secondary consequence of neoplastic meningitis, may also be observed. Characteristic findings on MRI are illustrated in Figs 1 and 2.<sup>7</sup>

In a cohort of 125 patients who had non-brain solid tumors, neoplastic meningitis, and positive findings on CSF cytology, as well as 40 patients with clinical neoplastic meningitis and negative findings on CSF cytology, MRI findings were abnormal in 40% of study patients with positive CSF cytology and 100% of study patients with MRI-defined neoplastic meningitis and negative CSF cytology.<sup>29</sup> The sensitivity of neuraxis MRI in detecting neoplastic meningitis varies between 40% and 86%.<sup>29,31–37</sup> Normal findings on MRI do not exclude the diagnosis of neoplastic men-

ingitis.<sup>1</sup> Co-existent brain metastases have been reported in 21% to 83% of patients with neoplastic meningitis.<sup>13,29,31-34,38,39</sup> The value of computed tomography (CT) with contrast of the cranium is limited in neoplastic meningitis (sensitivity rate, 23%–38%), and use of CT is restricted to the detection of hydrocephalus or if obtaining MRI is contraindicated.<sup>4,7,35,40</sup>

Radionuclide studies using indium, diethylene, and triamine penta-acetic or Tc macro-aggregated albumin permits the detection of CSF flow blocks present in 30% to 70% of patients with neoplastic meningitis.<sup>19</sup> In a cohort of 165 patients with neoplastic meningitis and solid tumors, the results of radioisotope CSF flow studies were abnormal in 25% of those with positive cytology results and in 28% of those whose disease was defined by MRI.<sup>29</sup> CSF blocks generally occur at the skull base, within the spinal subarachnoid space, and across the cerebral convexities.<sup>4,7,41</sup> Compared with patients without a disruption of CSF dynamics, patients with interruptions in CSF flow have a shorter survival.<sup>42</sup> Furthermore, a block of the CSF flow reduces the efficacy of the intra-CSF administration of treatment by limiting the distribution of the drug in the CNS and increasing treatment-related toxicity.<sup>4</sup> Nonetheless, radioisotope CSF flow dynamics is infrequently utilized. Determination of CSF flow interruption is relevant with respect to intra-CSF drug delivery, and, if documented, re-establishing normal CSF flow by treating the affected area with radiotherapy re-establishes CSF flow in 30% of intraspinal blocks and 50% of intracranial blocks.<sup>41</sup>

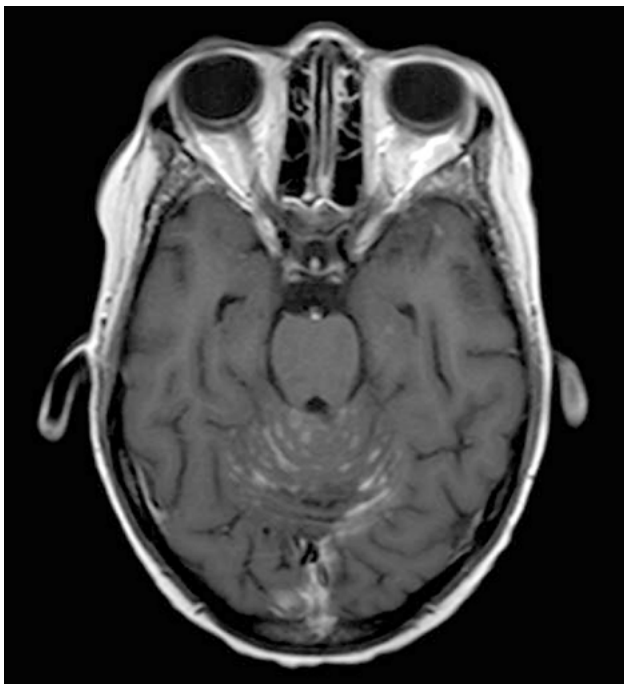


Fig 1. — Leptomeningeal sulcal enhancement at the cranial level on axial T1-weighted, gadolinium-enhanced magnetic resonance imaging of the brain.

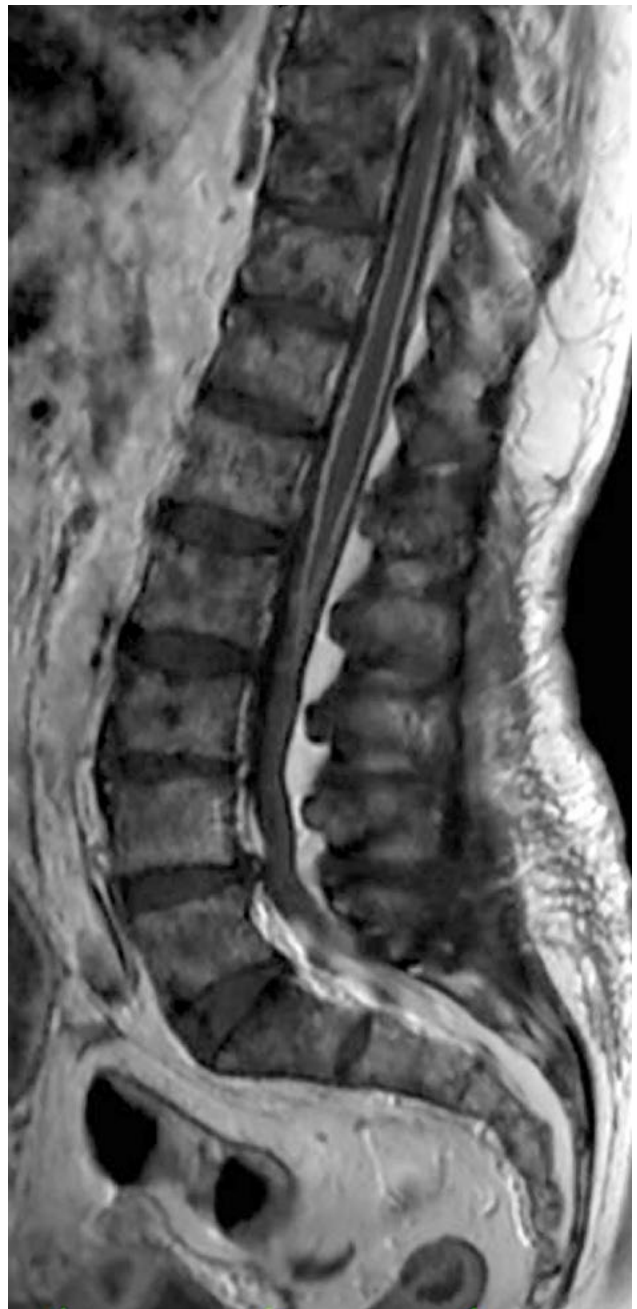

Fig 2. — Leptomeningeal perimedullary enhancement on sagittal T1-weighted, gadolinium-enhanced magnetic resonance imaging of the spinal column.

Normalizing CSF dynamics results in survival rates similar to that of patients initially without CSF flow interruption.<sup>41</sup>

### **Analysis of the Cerebrospinal Fluid**

Most patients (> 90%) with neoplastic meningitis manifest nonspecific CSF abnormalities, such as raised CSF opening pressure (46%), elevated protein levels (76%), decreased glucose levels (54%), or increased white blood cell counts (57%).<sup>4,7</sup> The finding of CTCs in the CSF can be used to establish the definitive diagnosis

of neoplastic meningitis.<sup>1</sup> The specificity rate of CSF cytology is high (80%–95%), but the sensitivity rate of initial lumbar puncture is estimated to be below 50%.<sup>1,4</sup> Using measures such as sampling a large volume of CSF (> 10 mL), avoiding a hemorrhagic CSF specimen, and prompt processing can improve the sensitivity of CSF cytology. Not obtaining a CSF sample from a clinically or radiologically symptomatic site may increase the rate of false-negative results on CSF cytology. Repeat lumbar puncture increases the likelihood of identifying CTCs to 80%.<sup>1,4,3</sup> Little benefit is obtained from obtaining a third CSF cytology sample.<sup>1,4,7,43</sup> In contemporary series of breast cancer–related neoplastic meningitis, the sensitivity rate of CSF cytology was reported to be 67% to 83%.<sup>31–37</sup>

Many CSF biomarkers have been examined for their use in neoplastic meningitis. Biomarkers may be nonspecific (eg,  $\alpha$ -glucuronidase, lactate dehydrogenase,  $\beta$ -2-microglobulin, carcinoembryonic antigen) or organ specific (eg, cancer antigen [CA] 15-3, CA 125, CA 19-9, CA 724,  $\alpha$ -fetoprotein, neuron-specific enolase, cytokeratin 19 fragment). However, no clear relationship exists between these various biomarkers and treatment response.<sup>7</sup> Proangiogenic molecules, such as vascular endothelial growth factor, urokinase plasminogen activator, and tissue plasminogen activator, have been evaluated with varying rates of sensitivities and specificities that do not appear to improve the performance of CSF cytology.<sup>7,44,45</sup> CSF metabolomics, protein profiling, micro-RNA studies, and genomic analysis may represent another method to aid in the diagnosis and treatment of neoplastic meningitis.<sup>46–49</sup> Identification of cell-surface, tumor-associated proteins in CSF is another method under investigation.<sup>50–53</sup> Due to lack of agreement on cutoff levels to standardize CSF sampling and processing with respect to the above-mentioned biomarkers, CSF cytology remains the gold standard for the detection of CTCs in the CSF.<sup>1,6,7</sup>

## Prognosis

Neoplastic meningitis often results in neurological impairments that both reduce quality of life and survival.<sup>4</sup> Thus, the goal of treatment is to improve or stabilize neurological function, maintain quality of life, and prolong survival. Deciding who to treat can be challenging. Fixed neurological deficits rarely improve with treatment, but the progression of neurological dysfunction may be arrested in some instances.<sup>4</sup> The median survival rate without treatment is 1 to 2 months, and often death is a consequence of progressive neurological dysfunction.<sup>4,6</sup> With treatment, median survival rates in neoplastic meningitis vary from 2 to 5 months in breast cancer, 3 to 6 months in NSCLC and 2 to 4 months in melanoma; however, these reported numbers predate the use of immunotherapy and targeted therapies (Table 2).<sup>3,16–20,31,33–39,54–67</sup> Cause

of death in patients with neoplastic meningitis may be due to the progression of neoplastic meningitis (24%–34%), progression of systemic disease (19%–44%), or both (22%–25%).<sup>22,58</sup>

Guidelines from the NCCN define poor and good risk factors for patients with neoplastic meningitis.<sup>21</sup> The poor risk group includes patients with low performance status; multiple, serious, or major neurological deficits; extensive, systemic disease with few treatment options; radiographic bulky CNS disease; neoplastic meningitis–related encephalopathy; and CSF dynamic flow obstructions.<sup>21</sup> Palliative care is suggested for all patients with a poor prognosis, whereas directed therapy should be considered for patients with a good prognosis.<sup>21</sup>

**Table 2. — Rates of Survival for Neoplastic Meningitis Due to Breast Cancer, Lung Cancer, or Melanoma Metastasis**

Tumor Type	Study	No. of Study Patients	Median Rate of Overall Survival <sup>a</sup>
Breast cancer	Boogerd <sup>65</sup>	35	18.3–30.3 wk (NA)
	Clatot <sup>34</sup>	24	150 d (9–561)
	Comte <sup>62</sup>	66	4.5 mo (0.1–50.0)
	De Azevedo <sup>36</sup>	60	3.3 mo (0.03–90.4)
	Gauthier <sup>35</sup>	91	4.5 mo (0–53)
	Jaeckle <sup>58</sup>	43	7 wk (NA)
	Kim <sup>59</sup>	30	8 mo (NA)
	Lara Medina <sup>55</sup>	49	7 wk (95% CI: 2.3–11.6 mo)
	Le Rhun <sup>31</sup>	103	3.8 mo (1 d–2.8 y)
	Lee <sup>37</sup>	68	4.1 mo (2.2–5.8)
	Meattini <sup>54</sup>	33	4.9 mo (0.3–27.7)
	Niwinska <sup>13</sup>	118	4.2 mo (1–37)
	Regierer <sup>60</sup>	27	9 wk (NA)
	Rudnicka <sup>33</sup>	67	16 wk (1–402)
	Torrejon <sup>63</sup>	38	2.6 mo (1.2–6.4)
Yust Katz <sup>56</sup>	103	4.2 mo (95% CI: 2.54–4.66)	
Lung cancer	Chuang <sup>67</sup>	34	5.1 wk (1 d–82 wk)
	Gwak <sup>57</sup>	105	3.0 mo (0.5–21.5)
	Hammerer <sup>64</sup>	26	57 wk (NA)
	Lee <sup>16</sup>	149	14 wk (95% CI: 12–16)
	Morris <sup>38</sup>	125	4.3 mo (1.5–6.7)
	Park <sup>39</sup>	50	3 mo (95% CI: 2–4)
	Riess <sup>17</sup>	30	6 mo (95% CI: 3–12)
	Sudo <sup>66</sup>	37	106 d (10–392)
	Umumera <sup>61</sup>	91	3.6 mo (0.1–34.4)
Melanoma	Chamberlain <sup>19</sup>	16	4 mo
	Harstad <sup>18</sup>	110	10 wk (95% CI: 8–14)
	Pape <sup>20</sup>	9	8 wk (1–168)

<sup>a</sup>Minimum to maximum survival or 95% CI. CI = confidence interval, NA = not applicable.

The type of primary cancer is also of prognostic importance. Breast cancer has a better prognosis than lung cancer or melanoma-related neoplastic meningitis.<sup>6,7</sup> Prolonged survival of 1 year or more may be observed in 7% to 24% of patients with breast cancer and neoplastic meningitis.<sup>33,35-37,54,60,68</sup> In breast cancer, multivariate analyses have demonstrated an association between survival and histological characteristics (grade and *HR* status), performance status, extent of systemic disease, treatment (number of prior chemotherapy regimens, receipt of combined treatment modalities, coadministration of systemic chemotherapy, and intra-CSF administration of chemotherapy), and initial response to treatment.<sup>13,31,33,35-37,54-56</sup> In lung cancer, multivariate analyses confirm that performance status, treatment (systemic therapy and intra-CSF administration of chemotherapy), and response to neoplastic meningitis-directed therapy were associated with longer survival.<sup>38,39</sup> In patients with *EGFR* mutations and neoplastic meningitis, epidermal growth factor receptor (EGFR) inhibitors may result in durable responses without the need for the intra-CSF administration of chemotherapy.<sup>61</sup> In a retrospective cohort of melanoma-associated neoplastic meningitis, a history of primary melanoma diagnosed on the trunk was correlated with shorter survival rates, whereas the intra-CSF administration of chemotherapy was associated with longer rates of survival.<sup>18</sup>

## Treatment

Combined treatment utilizing systemic chemotherapy (or targeted therapy), the intra-CSF administration of chemotherapy, and site-specific radiotherapy may improve rates of survival in patients otherwise determined to be good candidates for neoplastic meningitis-directed treatment. A number of randomized trials have been conducted in solid tumor-related neoplastic meningitis (Table 3).<sup>65,69-72</sup> Most of these trials included multiple tumor types, thereby limiting the applicability of the study results with respect to specific cancer-related neoplastic meningitis.<sup>65,69-72</sup> In addition, these trials varied with respect to methodology and the absence of any standardized criteria by which to evaluate response to treatment<sup>65,69-72</sup>; thus, the results cannot be generalized to specific groups of patients with neoplastic meningitis.

Because the progression of systemic disease is the primary cause of death in patients with neoplastic meningitis, treatment of systemic disease should not be neglected.<sup>73</sup> In general, patients with neoplastic meningitis who have a good performance status are treated with site-specific radiotherapy and disease-specific systemic therapy (chemotherapy or targeted therapy) that may treat both neoplastic meningitis and the systemic disease. The role of the intra-CSF administration in solid tumor-related neoplastic meningitis is not clearly defined. No prospective trial has established

**Table 3. — Select Randomized Trials of Neoplastic Meningitis-Related Solid Tumors**

Study	Design	Response	Toxicity
Boogerd <sup>65</sup>	N = 35 Breast cancer Systemic therapy and involved-field radiotherapy with intralumbar vs no intralumbar MTX	Improved stabilization: 59% vs 67% TTP <sup>a</sup> : 23 vs 24 wk OS: 18.3 vs 30.3 wk	Treatment complications: 47% vs 6%
Glantz <sup>91</sup>	N = 61 Solid tumors Cytarabine vs MTX	RR <sup>a</sup> : 26% vs 20% OS <sup>a</sup> : 105 vs 78 d TTP: 58 vs 30 d	Sensory/motor: 4% vs 10% Altered mental status: 5% vs 2% Headache: 4% vs 2% Bacterial meningitis: 10% vs 3%
Grossman <sup>70</sup>	N = 59 Solid tumors and lymphoma (in 90%) Intralumbar MTX vs thiotepa	Neurological improvements: None Median survival: 15.9 vs 14.1 wk	Serious toxicity (47%) similar between groups Mucositis and neurological complications more common in intralumbar MTX group
Hitchins <sup>69</sup>	N = 44 Solid tumors and lymphomas Intralumbar MTX vs MTX + cytarabine	RR <sup>a</sup> : 61% vs 45% Median survival <sup>a</sup> : 12 vs 7 wk	Nausea/vomiting: 36% vs 50% Septicemia, neutropenia: 9% vs 15% Mucositis: 14% vs 10% Pancytopenia: 9% vs 10% AEs related to reservoir: Blocked Ommaya: 17% Intracranial hemorrhage: 11%
Shapiro <sup>72</sup>	103 solid tumors Cytarabine vs MTX	Intraventricular cytarabine vs intraventricular MTX PFS <sup>a</sup> : 35 vs 37.5 d	Drug-related AEs: 48% vs 60% Serious AEs: 86% vs 77%

<sup>a</sup>No significant differences between groups.

AE = adverse event, MTX = methotrexate, OS = overall survival, PFS = progression-free survival, RR = response rate, TTP = time to progression.

the superiority of the intra-CSF administration of chemotherapy relative to systemic therapy. Thus, treatment of neoplastic meningitis should be individualized to the general and neurological status of the patient, the available therapeutic options for systemic disease, and the manner of neurological presentation.

### **Symptomatic Treatment**

Symptomatic treatment is indicated for all patients with neoplastic meningitis. Pain is treated using opioid analgesics, tricyclic antidepressants, or antiepileptic drugs when present. Corticosteroids may improve radicular pain. The contribution of corticosteroids is limited in neoplastic meningitis because, unlike in brain metastases, neoplastic meningitis does not result in vasogenic edema. However, steroids are useful for the treatment of associated brain metastasis or epidural spinal compression.<sup>4</sup> Focal radiotherapy of symptomatic sites may also provide pain relief. Prophylactic antiepileptic drugs are not indicated, except in patients with seizures and, if used, non-enzyme-inducing drugs are preferred to mitigate pharmacodynamic interaction with systemic therapies. Symptomatic hydrocephalus can be treated by a ventriculoperitoneal shunt or, in some instances, whole-brain/skull-base radiotherapy.<sup>4,7</sup>

### **Surgery**

The main surgical indications in neoplastic meningitis include placement of a ventriculoperitoneal shunt for symptomatic hydrocephalus and implantation of ventricular-access devices (eg, Ommaya reservoir) to facilitate the intra-CSF administration of therapy. In 1 report, diverting CSF improved survival in patients with neoplastic meningitis.<sup>74</sup> Complications of a ventriculoperitoneal shunt include possible peritoneal dissemination; however, data from studies of medulloblastoma indicate the absence of peritoneal metastases, nor do any data in the medical literature on neoplastic meningitis suggest a similar seeding pattern.<sup>75</sup>

Ventricular-access devices offer several advantages for the intra-CSF administration of chemotherapy. After lumbar puncture, the intra-CSF administration of a drug may unknowingly be placed into the epidural or subdural space in up to 12% of patients.<sup>76</sup> Furthermore, following intralumbar drug administration, the drug distribution may be not uniform with the variable drug concentration observed in the intracranial compartment.<sup>4,7</sup> These pharmacodynamic aspects of intralumbar drug delivery may partly explain the benefit seen in progression-free survival after the intraventricular administration of select agents.<sup>76</sup> Placing a ventricular-access device is a relatively pain-free procedure.

Ventricular-access devices may also be used in the setting of thrombocytopenia, a relative contraindication for intralumbar drug administration.<sup>7</sup> In a cohort of 112 patients (a median of 9 injections per study pa-

tient), of whom 72% were treated with both systemic and intraventricular chemotherapy, 11 cases of complications were observed, including 7 infections related to the ventricular-access device.<sup>77</sup> These results confirmed the safety of ventricular-access devices in patients with neoplastic meningitis. Rarely, intracranial hemorrhage, symptomatic leukoencephalopathy, or malposition or obstruction of the catheter can be observed with ventricular-access devices in patients with neoplastic meningitis.<sup>4,77</sup>

### **Radiotherapy**

Radiotherapy is indicated for the treatment of symptomatic sites of disease, bulky disease defined by MRI, or to correct CSF flow blocks demonstrated by radioisotope CSF flow dynamics.<sup>1,4,78</sup> Radiotherapy is indicated for cauda equina or skull-base syndromes, even in the absence of correlated radiographical signs.<sup>4</sup> Radiotherapy often provides pain relief and may help stabilize but does not typically improve neoplastic meningitis-related neurological disease.<sup>4</sup>

Bulky radiographical disease is another indication for radiotherapy because the intra-CSF administration of chemotherapy has limited diffusion (< 3 mm) into tumor nodules and is limited in its effectiveness.<sup>4</sup> Correction of CSF flow obstruction is yet another indication for radiotherapy in neoplastic meningitis, and, if normalized, outcomes are similar to those seen in patients with normal CSF flow dynamics.<sup>42</sup>

Stereotactic radiosurgery and fractionated stereotactic radiotherapy have little utility in managing neoplastic meningitis except in co-existent brain metastasis.<sup>1,78</sup> In general, CNS site-specific radiotherapy is well tolerated, but use of more extensive radiation treatment fields, such as craniospinal irradiation, have not improved outcomes in solid tumor-related neoplastic meningitis and may result in serious adverse events (eg, myelosuppression, gastrointestinal toxicity).<sup>1,4,6,7</sup>

Whole-brain radiotherapy may ameliorate neoplastic meningitis-related communicating hydrocephalus secondary to the interruption of CSF flow over the convexity of the brain. Whole-brain radiotherapy can be used to treat co-existent brain metastasis. In a retrospective cohort of patients with NSCLC and neoplastic meningitis, whole-brain radiotherapy did not prolong survival when used as a single-modality therapy for neoplastic meningitis.<sup>38</sup>

### **Systemic Therapy**

The selection of systemic chemotherapy to treat neoplastic meningitis is based on the chemosensitivity profile of the primary tumor and the ability of the therapeutic agent to cross the blood-CSF barrier. Temozolomide, an alkylator chemotherapeutic agent known to cross the blood-CSF barrier, failed in a phase 2, non-randomized study of patients with neoplastic meninge-

tis related to either breast cancer or NSCLC.<sup>79</sup> It is likely that it failed due to the inactivity of temozolomide in these cancers.<sup>79</sup> Cytotoxic concentrations can also be achieved in the CSF with intravenous high-dose methotrexate or cytarabine, but these regimens have limited effectiveness, except in breast cancer, and often result in significant rates of toxicity.<sup>7</sup>

**Breast Cancer:** Capecitabine, a fluoropyrimidine that can penetrate the CNS, has shown durable responses in small case series of breast cancer–related neoplastic meningitis.<sup>80,81</sup> Taxane-based chemotherapies (paclitaxel and docetaxel, which are common agents used to treat breast cancer), do not cross the blood–CSF barrier and have no efficacy in treating neoplastic meningitis.<sup>82</sup> Responses in patients with neoplastic meningitis after endocrine therapy (tamoxifen, letrozole, anastrozole, megestrol) have occasionally been reported, but most often at the initial presentation of neoplastic meningitis.<sup>7</sup> Breast cancer has acquired resistance to these therapies.<sup>7</sup>

Anti-erb-b2 receptor tyrosine kinase 2 (ERBB2) therapies (eg, trastuzumab, pertuzumab, lapatinib) are approved for use in metastatic *ERBB2*-positive breast cancer. However, no systemic anti-ERBB2 agent has been evaluated in neoplastic meningitis, except for responses observed in brain metastases.<sup>83,84</sup> Several authors have reported a potential role of bevacizumab alone or in combination with chemotherapy for certain patients with neoplastic meningitis, and the results from several prospective studies evaluating bevacizumab in breast cancer–related neoplastic meningitis are forthcoming (NCT00924820, NCT01281696).<sup>85–89</sup>

**Lung Cancer:** The impact of systemic chemotherapy in the treatment of lung cancer–related neoplastic meningitis is unclear, but anecdotal responses have been observed following platinum-couplet chemotherapy.<sup>90</sup> Some data suggest that patients treated with select systemic therapies containing pemetrexed, bevacizumab, or a tyrosine kinase inhibitor have improved overall survival in select patients, but the effectiveness of these therapies in patients with neoplastic meningitis is not certain.<sup>17</sup> Nonetheless, responses to pemetrexed and bevacizumab have been observed in small case reports of NSCLC-related neoplastic meningitis.<sup>16,91</sup> Results from a prospective study of bevacizumab for the treatment of neoplastic meningitis that enrolled patients with lung cancer and neoplastic meningitis are forthcoming (NCT00924820).

Activity of the EGFR–tyrosine kinase inhibitors erlotinib and gefitinib at normal and higher doses was observed in patients with activating mutations of *EGFR* and NSCLC-related neoplastic meningitis.<sup>16,32,38</sup> However, whether standard-dose or pulsatile, high-dose regimens of EGFR inhibitors are of utility has not yet been defined.<sup>92</sup> Erlotinib may achieve higher CSF concentrations than gefitinib, and this drug has potential in neo-

plastic meningitis.<sup>16</sup> CNS responses with erlotinib after prior progression on gefitinib and vice versa have been reported.<sup>93</sup> Second-generation EGFR inhibitors such as afatinib (combined with cetuximab) also have activity in lung cancer–related neoplastic meningitis.<sup>94</sup> Third-generation EGFR inhibitors exist that have both improved CNS penetration and activity against the T790M mutation that commonly results in resistance to EGFR inhibition, and these investigational drugs may prove to be effective for both brain metastases and neoplastic meningitis.<sup>95</sup> In a single case series, response to an anaplastic lymphoma kinase inhibitor was observed in the setting of neoplastic meningitis and NSCLC.<sup>96</sup>

**Melanoma:** Standard systemic chemotherapy for the management of melanoma includes temozolomide, dacarbazine, and fotemustine. However, systemic chemotherapy has limited activity in CNS metastases. Immunotherapy with anti-CTLA-4 (ipilimumab) alone or in combination with fotemustine has demonstrated efficacy in patients with minimal symptomatic brain metastasis.<sup>97,98</sup> Similar responses have been observed in brain metastasis treated with vemurafenib and dabrafenib.<sup>99,100</sup> In patients with both systemic and CNS metastases, similar response rates (78% and 90%) were observed when they were treated with dabrafenib.<sup>101</sup> Cases of melanoma-related neoplastic meningitis responding to ipilimumab or dabrafenib have been reported, but whether targeted therapies can substitute for standard treatment has not yet been determined.<sup>102</sup>

### **Intracerebrospinal Fluid Administration of Chemotherapy**

The intra-CSF administration of chemotherapy is a type of regional or intracavitary administration associated with minimal rates of systemic toxicity; it also produces high levels of the drug in the CSF compartment.<sup>103</sup> Although it is frequently used for the treatment of neoplastic meningitis, no prospective trials have demonstrated any benefit of intra-CSF administration of chemotherapy in patients with solid tumor–related neoplastic meningitis. Four drugs are commonly used in routine practice for intra-CSF administration and include methotrexate, cytarabine and its liposomal form, and thiotepe (Table 4). The length of treatment following the successful induction has not yet been defined for neoplastic meningitis, wherein patients have converted from positive to negative findings on CSF cytology and are otherwise clinically stable. Intra-CSF administration of chemotherapy was identified as a significant prognostic factor in the treatment of patients with NSCLC and neoplastic meningitis.<sup>38</sup> Several trials in adults with neoplastic meningitis have not demonstrated any superiority with respect to either response or survival when comparing combination therapy with single-agent therapy.<sup>7,65,69,104</sup> Common to all chemotherapy administered into the CSF, and, in par-



**Table 4. — Select Dosages for the Intra-CSF Administration of Chemotherapy**

Drug	Pharmacology	Half-Life	Regimen
Cytarabine	Cell-cycle specific Pyrimidine nucleoside analogue	—	25–100 mg twice weekly for 4 wk, 25–100 mg once wkly for 4 wk, then 25–100 mg once monthly
Liposomal cytarabine <sup>a</sup>	Cell-cycle specific Pyrimidine nucleoside analogue	14–21 d	50 mg every 2 wk for 8 wk, then 50 mg once every 4 wk <sup>b</sup>
Methotrexate <sup>c</sup>	Cell-cycle specific Folate antimetabolite	4.5–8 h	<i>Standard regimen:</i> 10–15 mg twice weekly for 4 wk, then 10–15 mg once weekly for 4 wk, then 10–15 mg once monthly <i>Low-dose regimen:</i> 2 mg/d (d 1–5) every other wk <i>High-dose regimen:</i> 15 mg/d (d 1–5) every other wk
Thiotepa	Alkylating ethyleneimine compound Not cell-cycle specific	3–4 min	10 mg twice weekly for 4 wk, then 10 mg once weekly for 4 wk, then 10 mg once a month

<sup>a</sup>Prophylaxis with corticosteroids is required.

<sup>b</sup>The dose may be reduced to 25 mg per injection to improve tolerance.

<sup>c</sup>Prophylaxis with acid folinic is required.

CSF = cerebrospinal fluid.

ticular, the long half-life agent liposomal cytarabine, is treatment-related, transient, aseptic chemical meningitis that can be mitigated by the concomitant oral administration of dexamethasone. A challenge with the current intra-CSF administration of chemotherapy is the limited efficacy of these agents in solid tumors.<sup>1</sup> Another limitation of intra-CSF chemotherapy when used for the treatment of neoplastic meningitis is its limited penetration (1–3 mm) into tumor nodules, such that the intra-CSF administration of chemotherapy is relatively ineffective in MRI-defined bulky leptomeningeal disease. In patients with CSF flow blocks defined by radioisotope studies, the intra-CSF administration of chemotherapy can be associated with an increased risk of neurotoxicity.

Although these agents are rarely used, the intra-CSF administration of alternative agents (etoposide, topotecan, diaziquone, mafosfamide, nimustine, hydroperoxycyclophosphamide, mercaptopurine, dacarbazine, gemcitabine, interferon  $\alpha$ ) have either failed or shown similar activity to standard agents used in neoplastic meningitis.<sup>7</sup> The continuous ventricular infusion of methotrexate may represent an alternative, pharmacologically rational approach to treating neoplastic meningitis, because few CTCs are present in the active cell cycle.<sup>57</sup> Intra-CSF administration of targeted therapies (trastuzumab in breast cancer, interleukin 2 in melanoma, and panitumumab in NSCLC) has been used in neoplastic meningitis, but it has been described in case reports alone.<sup>7,105,106</sup> Two phase 1/2 studies are researching *ERBB2*-positive breast cancer and neoplastic meningitis to define the safety and efficacy of the intra-CSF administration of trastuzumab (NCT01325207, NCT01373710).

## Conclusions

The incidence of neoplastic meningitis is increasing due to an improvement in the overall survival rate of

patients with cancer, which, in part, reflects the fact that more effective anticancer therapies do not cross the brain–cerebrospinal fluid (CSF) barrier.<sup>2,3</sup> The diagnosis of neoplastic meningitis remains challenging, as reflected by its underdiagnosis and the limited sensitivity of CSF cytology and neuraxis radiography in establishing the diagnosis. Without treatment, neoplastic meningitis is associated with poor outcomes and progressive, neurological death. Determining which patients with neoplastic meningitis are likely to benefit from directed therapy is challenging; however, the extent of systemic disease, type of treatment, the neurological presentation, and the disease burden are all factors identified as being useful for proper patient selection. Treatment options can include chemotherapy (systemic and intra-CSF administration), site-specific radiotherapy, and symptom-directed care. Limited case reports suggest that immunotherapy and cancer-specific targeted therapies may be effective in the treatment of neoplastic meningitis in certain patients — and prospective studies are testing this hypothesis. Proposals for assessing treatment response in neoplastic meningitis could help to standardize the evaluation of neoplastic meningitis and improve clinical trial design so as to better define the role of novel therapies in neoplastic meningitis.

## References

1. Chamberlain M, Soffiotti R, Raizer J, et al. Leptomeningeal metastasis: a response assessment in neuro-oncology critical review of endpoints and response criteria of published randomized clinical trials. *Neuro-Oncol*. 2014;16(9):1176-1185.
2. Omuro AM, Kris MG, Miller VA, et al. High incidence of disease recurrence in the brain and leptomeninges in patients with nonsmall cell lung carcinoma after response to gefitinib. *Cancer*. 2005;103(11):2344-2348.
3. Lai R, Dang CR, Malkin MG, et al. The risk of central nervous system metastases after trastuzumab therapy in patients with breast carcinoma. *Cancer*. 2004;101(4):810-816.
4. Chamberlain MC. Leptomeningeal metastasis. *Curr Opin Oncol*. 2010;22(6):627-635.
5. Glass JP, Melamed M, Chernik NL, et al. Malignant cells in cerebrospinal fluid (CSF): the meaning of a positive CSF cytology. *Neurology*.

1979;29(10):1369-1375.

6. Roth P, Weller M. Management of neoplastic meningitis. *Chin Clin Oncol.* 2015;4(2):26.

7. Le Rhun E, Taillibert S, Chamberlain MC. Carcinomatous meningitis: leptomeningeal metastases in solid tumors. *Surg Neurol Int.* 2013;4(suppl 4):S265-S288.

8. Gleissner B, Chamberlain MC. Neoplastic meningitis. *Lancet Neurol.* 2006;5(5):443-452.

9. van der Ree TC, Dippel DW, Avezaat CJ, et al. Leptomeningeal metastasis after surgical resection of brain metastases. *J Neurol Neurosurg Psychiatry.* 1999;66(2):225-227.

10. Suki D, Hatiboglu MA, Patel AJ, et al. Comparative risk of leptomeningeal dissemination of cancer after surgery or stereotactic radiosurgery for a single supratentorial solid tumor metastasis. *Neurosurgery.* 2009;64(4):664-674-676.

11. Trifiletti DM, Romano KD, Xu Z, et al. Leptomeningeal disease following stereotactic radiosurgery for brain metastases from breast cancer. *J Neurooncol.* 2015;124(3):421-427.

12. Ojerholm E, Lee JYK, Thawani JP, et al. Stereotactic radiosurgery to the resection bed for intracranial metastases and risk of leptomeningeal carcinomatosis. *J Neurosurg.* 2014;121(suppl):75-83.

13. Nawińska A, Rudnicka H, Murawska M. Breast cancer leptomeningeal metastasis: propensity of breast cancer subtypes for leptomeninges and the analysis of factors influencing survival. *Med Oncol.* 2013;30(1):408.

14. Le Rhun E, Taillibert S, Zairi F, et al. Clinicopathological features of breast cancers predict the development of leptomeningeal metastases: a case-control study. *J Neurooncol.* 2011;105(2):309-315.

15. Christoph DC, Reckamp KL. Intraventricular chemotherapy for leptomeningeal carcinomatosis from lung cancer: a feasible and beneficial treatment option? *J Thorac Oncol.* 2013;8(5):523-524.

16. Lee SJ, Lee J-I, Nam D-H, et al. Leptomeningeal carcinomatosis in non-small-cell lung cancer patients: impact on survival and correlated prognostic factors. *J Thorac Oncol.* 2013;8(2):185-191.

17. Riess JW, Nagpal S, Iv M, et al. Prolonged survival of patients with non-small-cell lung cancer with leptomeningeal carcinomatosis in the modern treatment era. *Clin Lung Cancer.* 2014;15(3):202-206.

18. Harstad L, Hess KR, Groves MD. Prognostic factors and outcomes in patients with leptomeningeal melanomatosis. *Neuro-Oncol.* 2008;10(6):1010-1018.

19. Chamberlain M, Kormanik P. Leptomeningeal metastases due to melanoma. *Int J Oncol.* 1996;9(3):505-510.

20. Pape E, Desmedt E, Zairi F, et al. Leptomeningeal metastasis in melanoma: a prospective clinical study of nine patients. *In Vivo.* 2012;26(6):1079-1086.

21. National Comprehensive Cancer Network (NCCN). *NCCN Clinical Practice Guidelines in Oncology: Central Nervous System Cancers.* v1.2016. [https://www.nccn.org/professionals/physician\\_gls/pdf/cns.pdf](https://www.nccn.org/professionals/physician_gls/pdf/cns.pdf). Accessed December 7, 2016.

22. Groves MD. New strategies in the management of leptomeningeal metastases. *Arch Neurol.* 2010;67(3):305-312.

23. Jaeckle KA. Neoplastic meningitis from systemic malignancies: diagnosis, prognosis, and treatment. *Semin Oncol.* 2006; 33(3):312-323.

24. Wasserstrom WR, Glass JP, Posner JB. Diagnosis and treatment of leptomeningeal metastases from solid tumors: experience with 90 patients. *Cancer.* 1982;49(4):759-772.

25. Little JR, Dale AJ, Okazaki H. Meningeal carcinomatosis. Clinical manifestations. *Arch Neurol.* 1974;30(2):138-143.

26. van Oostenbrugge RJ, Twijnstra A. Presenting features and value of diagnostic procedures in leptomeningeal metastases. *Neurology* 1999;53(2):382-385.

27. Balm M, Hammack J. Leptomeningeal carcinomatosis: presenting features and prognostic factors. *Arch Neurol.* 1996;53(7):626-632.

28. Groves MD. *Advances in Treating Leptomeningeal Metastases: Educational Book.* Alexandria, VA: American Society of Clinical Oncology; 2008:80-87.

29. Chamberlain MC. Comprehensive neuraxis imaging in leptomeningeal metastasis: a retrospective case series. *CNS Oncol.* 2013;2(2):121-128.

30. Chamberlain MC. Leptomeningeal metastasis. *Curr Opin Neurol.* 2009;22(6):665-674.

31. Le Rhun E, Taillibert S, Zairi F, et al. A retrospective case series of 103 consecutive patients with leptomeningeal metastasis and breast cancer. *J Neurooncol.* 2013;113(1):83-92.

32. Clarke JL, Perez HR, Jacks LM, et al. Leptomeningeal metastases in the MRI era. *Neurology.* 2010;74(18):1449-1454.

33. Rudnicka H, Nawińska A, Murawska M. Breast cancer leptomeningeal metastasis--the role of multimodality treatment. *J Neurooncol.* 2007;84(1):57-62.

34. Clatof F, Philippin-Lauridant G, Ouvrier M-J, et al. Clinical improvement and survival in breast cancer leptomeningeal metastasis correlate with the cytologic response to intrathecal chemotherapy. *J Neurooncol.* 2009;95(3):421-426.

35. Gauthier H, Guilhaume MN, Bidard FC, et al. Survival of breast cancer patients with meningeal carcinomatosis. *Ann Oncol.* 2010;21(11):2183-2187.

36. de Azevedo CRAS, Cruz MRS, Chinen LTD, et al. Meningeal carci-

nomatosis in breast cancer: prognostic factors and outcome. *J Neurooncol.* 2011;104(2):565-572.

37. Lee S, Ahn HK, Park YH, et al. Leptomeningeal metastases from breast cancer: intrinsic subtypes may affect unique clinical manifestations. *Breast Cancer Res Treat.* 2011;129(3):809-817.

38. Morris PG, Reiner AS, Szenberg OR, et al. Leptomeningeal metastasis from non-small cell lung cancer: survival and the impact of whole brain radiotherapy. *J Thorac Oncol.* 2012;7(2):382-385.

39. Park JH, Kim YJ, Lee J-O, et al. Clinical outcomes of leptomeningeal metastasis in patients with non-small cell lung cancer in the modern chemotherapy era. *Lung Cancer.* 2012;76(3):387-392.

40. Sze G, Soletsky S, Bronen R, et al. MR imaging of the cranial meninges with emphasis on contrast enhancement and meningeal carcinomatosis. *AJR Am J Roentgenol.* 1989;153(5):1039-1049.

41. Chamberlain MC, Kormanik P, Jaeckle KA, et al. 111Indium-diethylenetriamine pentaacetic acid CSF flow studies predict distribution of intrathecally administered chemotherapy and outcome in patients with leptomeningeal metastases. *Neurology.* 1999;52(1):216-217.

42. Chamberlain MC, Kormanik PA. Prognostic significance of 111indium-DTPA CSF flow studies in leptomeningeal metastases. *Neurology.* 1996;46(6):1674-1677.

43. Glantz MJ, Cole BF, Glantz LK, et al. Cerebrospinal fluid cytology in patients with cancer: minimizing false-negative results. *Cancer.* 1998;82(4):733-739.

44. Groves MD, Hess KR, Puduvali VK, et al. Biomarkers of disease: cerebrospinal fluid vascular endothelial growth factor (VEGF) and stromal cell derived factor (SDF)-1 levels in patients with neoplastic meningitis (NM) due to breast cancer, lung cancer and melanoma. *J Neurooncol.* 2009;94(2):229-234.

45. Herrlinger U, Wiendl H, Renninger M, et al. Vascular endothelial growth factor (VEGF) in leptomeningeal metastasis: diagnostic and prognostic value. *Br J Cancer.* 2004;91(2):219-224.

46. An YJ, Cho HR, Kim TM, et al. An NMR metabolomics approach for the diagnosis of leptomeningeal carcinomatosis in lung adenocarcinoma cancer patients. *Int J Cancer.* 2015;136(1):162-171.

47. Römpf A, Dekker L, Taban I, et al. Identification of leptomeningeal metastasis-related proteins in cerebrospinal fluid of patients with breast cancer by a combination of MALDI-TOF, MALDI-FTICR and nanoLC-FTICR MS. *Proteomics.* 2007;7(3):474-481.

48. Teplyuk NM, Mollenhauer B, Gabriely G, et al. MicroRNAs in cerebrospinal fluid identify glioblastoma and metastatic brain cancers and reflect disease activity. *Neuro-Oncol.* 2012;14(6):689-700.

49. Magbanua MJM, Melisko M, Roy R, et al. Molecular profiling of tumor cells in cerebrospinal fluid and matched primary tumors from metastatic breast cancer patients with leptomeningeal carcinomatosis. *Cancer Res.* 2013;73(23):7134-7143.

50. Patel AS, Allen JE, Dicker DT, et al. Identification and enumeration of circulating tumor cells in the cerebrospinal fluid of breast cancer patients with central nervous system metastases. *Oncotarget.* 2011;2(10):752-760.

51. Le Rhun E, Massin F, Tu Q, et al. Development of a new method for identification and quantification in cerebrospinal fluid of malignant cells from breast carcinoma leptomeningeal metastasis. *BMC Clin Pathol.* 2012;12:21.

52. Le Rhun E, Tu Q, De Carvalho Bittencourt M, et al. Detection and quantification of CSF malignant cells by the CellSearch technology in patients with melanoma leptomeningeal metastasis. *Med Oncol.* 2013;30(2):538.

53. Nayak L, Fleisher M, Gonzalez-Espinoza R, et al. Rare cell capture technology for the diagnosis of leptomeningeal metastasis in solid tumors. *Neurology.* 2013;80(17):1598-1605.

54. Meattini I, Livi L, Saieva C, et al. Prognostic factors and clinical features in patients with leptomeningeal metastases from breast cancer: a single center experience. *J Chemother Florence Italy.* 2012;24(5):279-284.

55. Lara-Medina F, Crismatt A, Villarreal-Garza C, et al. Clinical features and prognostic factors in patients with carcinomatous meningitis secondary to breast cancer. *Breast J.* 2012;18(3):233-241.

56. Yust-Katz S, Garcarena P, Liu D, et al. Breast cancer and leptomeningeal disease (LMD): hormone receptor status influences time to development of LMD and survival from LMD diagnosis. *J Neurooncol.* 2013;114(2):229-235.

57. Gwak H-S, Joo J, Kim S, et al. Analysis of treatment outcomes of intraventricular chemotherapy in 105 patients for leptomeningeal carcinomatosis from non-small-cell lung cancer. *J Thorac Oncol.* 2013;8(5):599-605.

58. Jaeckle KA, Phuphanich S, Bent MJ, et al. Intrathecal treatment of neoplastic meningitis due to breast cancer with a slow-release formulation of cytarabine. *Br J Cancer.* 2001;84(2):157-163.

59. Kim HJ, Im SA, Keam B, et al. Clinical outcome of central nervous system metastases from breast cancer: differences in survival depending on systemic treatment. *J Neurooncol.* 2012;106(2):303-313.

60. Regierer AC, Stroux A, Kühnhardt D, et al. Contrast-enhancing meningeal lesions are associated with longer survival in breast cancer-related leptomeningeal metastasis. *Breast Care.* 2008;3(2):118-123.

61. Umemura S, Tsubouchi K, Yoshioka H, et al; Okayama Lung Cancer Study Group. Clinical outcome in patients with leptomeningeal metastasis from non-small cell lung cancer. *Lung Cancer.* 2012;77(1):134-139.

62. Comte A, Jdid W, Guilhaume MN, et al. Survival of breast cancer patients with meningeal carcinomatosis treated by intrathecal thiotepa. *J Neurooncol*. 2013;115(3):445-452.
63. Torrejón D, Oliveira M, Cortes J, et al. Implication of breast cancer phenotype for patients with leptomeningeal carcinomatosis. *Breast Edinb Scotl*. 2013;22(1):19-23.
64. Hammerer V, Pauli G, Quoix E. Retrospective study of a series of 26 carcinomatous meningitis secondary to lung cancer [in French]. *Bull Cancer (Paris)*. 2005;92(11):989-994.
65. Boogerd W, van den Bent MJ, Koehler PJ, et al. The relevance of intraventricular chemotherapy for leptomeningeal metastasis in breast cancer: a randomised study. *Eur J Cancer*. 2004;40(18):2726-2733.
66. Sudo J, Honmura Y, Kurimoto F, et al. Meningeal carcinomatosis in patients with breast cancer [in Japanese]. *Nihon Kokyūki Gakkai Zasshi*. 2006;44(11):795-799.
67. Chuang TY, Yu CJ, Shih JY, et al. Cytologically proven meningeal carcinomatosis in patients with lung cancer: clinical observation of 34 cases. *J Formos Med Assoc*. 2008;107(11):851-856.
68. Le Rhun E, Taillibert S, Zairi F, et al. Prolonged survival of patients with breast cancer-related leptomeningeal metastases. *Anticancer Res*. 2013;33(5):2057-2063.
69. Hitchins RN, Bell DR, Woods RL, Levi JA. A prospective randomized trial of single-agent versus combination chemotherapy in meningeal carcinomatosis. *J Clin Oncol*. 1987;5(10):1655-1662.
70. Grossman SA, Finkelstein DM, Ruckdeschel JC, et al; Eastern Cooperative Oncology Group. Randomized prospective comparison of intraventricular methotrexate and thiotepa in patients with previously untreated neoplastic meningitis. *J Clin Oncol*. 1993;11(3):561-569.
71. Glantz MJ, Jaecckle KA, Chamberlain MC, et al. A randomized controlled trial comparing intrathecal sustained-release cytarabine (DepoCyt) to intrathecal methotrexate in patients with neoplastic meningitis from solid tumors. *Clin Cancer Res*. 1999;5(11):3394-3402.
72. Shapiro WR, Schmid M, Glantz M, et al. A randomized phase III/IV study to determine benefit and safety of cytarabine liposome injection for treatment of neoplastic meningitis. *J Clin Oncol*. 2006;24(suppl):1528.
73. Siegal T, Lossos A, Pfeffer MR. Leptomeningeal metastases: analysis of 31 patients with sustained off-therapy response following combined-modality therapy. *Neurology*. 1994;44(8):1463-1469.
74. Jung T-Y, Chung W-K, Oh I-J. The prognostic significance of surgically treated hydrocephalus in leptomeningeal metastases. *Clin Neurol Neurosurg*. 2014;119:80-83.
75. Berger MS, Baumeister B, Geyer JR, et al. The risks of metastases from shunting in children with primary central nervous system tumors. *J Neurosurg*. 1991;74(6):872-877.
76. Glantz MJ, Van Horn A, Fisher R, et al. Route of intracerebrospinal fluid chemotherapy administration and efficacy of therapy in neoplastic meningitis. *Cancer*. 2010;116(8):1947-1952.
77. Zairi F, Le Rhun E, Bertrand N, et al. Complications related to the use of an intraventricular access device for the treatment of leptomeningeal metastases from solid tumor: a single centre experience in 112 patients. *J Neurooncol*. 2015;124(2):317-323.
78. Souchon R, Feyer P, Thomssen C, et al. Clinical recommendations of DEGRO and AGO on preferred standard palliative radiotherapy of bone and cerebral metastases, metastatic spinal cord compression, and leptomeningeal carcinomatosis in breast cancer. *Breast Care*. 2010;5(6):401-407.
79. Segura PP, Gil M, Balañá C, et al. Phase II trial of temozolomide for leptomeningeal metastases in patients with solid tumors. *J Neurooncol*. 2012;109(1):137-142.
80. Ekenel M, Hormigo AM, Peak S, et al. Capecitabine therapy of central nervous system metastases from breast cancer. *J Neurooncol*. 2007;85(2):223-227.
81. Tanaka Y, Oura S, Yoshimasu T, et al. Response of meningeal carcinomatosis from breast cancer to capecitabine monotherapy: a case report. *Case Rep Oncol*. 2013;6(1):1-5.
82. Kosmas C, Malamos NA, Tsavaris NB, et al. Leptomeningeal carcinomatosis after major remission to taxane-based front-line therapy in patients with advanced breast cancer. *J Neurooncol*. 2002;56(3):265-273.
83. Bartsch R, Berghoff A, Pluschnig U, et al. Impact of anti-HER2 therapy on overall survival in HER2-overexpressing breast cancer patients with brain metastases. *Br J Cancer*. 2012;106(1):25-31.
84. Lin NU, Diéras V, Paul D, et al. Multicenter phase II study of lapatinib in patients with brain metastases from HER2-positive breast cancer. *Clin Cancer Res*. 2009;15(4):1452-1459.
85. Labidi SI, Bachelot T, Ray-Coquard I, et al. Bevacizumab and paclitaxel for breast cancer patients with central nervous system metastases: a case series. *Clin Breast Cancer*. 2009;9(2):118-121.
86. Vincent A, Lesser G, Brown D, et al. Prolonged regression of metastatic leptomeningeal breast cancer that has failed conventional therapy: a case report and review of the literature. *J Breast Cancer*. 2013;16(1):122-126.
87. Chen IC, Lin CH, Jan IS, et al. Bevacizumab might potentiate the chemotherapeutic effect in breast cancer patients with leptomeningeal carcinomatosis. *J Formos Med Assoc*. 2016;115(4):243-248.
88. Le Rhun E, Taillibert S, Boulanger T, et al. Prolonged response and restoration of functional independence with bevacizumab plus vinorelbine as third-line treatment for breast cancer-related leptomeningeal metastases. *Case Rep Oncol*. 2015;8(1):72-77.
89. Groves MD, DeGroot J, Tremont I, et al. A pilot study of systemically administered bevacizumab in patients with neoplastic meningitis (NM): Imaging, clinical, CSF and biomarker outcome. Presented at: 16th Annual Meeting of the Society for Neuro-Oncology; Orange County, CA; November 17–20, 2011. Poster OT-02.
90. Bai C, Shi H, Liu D, et al. Gemcitabine plus oxaliplatin for the treatment of leptomeningeal metastases of non-small cell lung cancer: A case report and review of the literature. *Oncol Lett*. 2013;5(5):1559-1561.
91. Barlesi F, Gervais R, Lena H, et al. Pemetrexed and cisplatin as first-line chemotherapy for advanced non-small-cell lung cancer (NSCLC) with asymptomatic inoperable brain metastases: a multicenter phase II trial (GFPC 07-01). *Ann Oncol*. 2011;22(11):2466-2470.
92. Grommes C, Oxnard GR, Kris MG, et al. "Pulsatile" high-dose weekly erlotinib for CNS metastases from EGFR mutant non-small cell lung cancer. *Neuro-Oncol*. 2011;13(12):1364-1369.
93. Nakamichi S, Kubota K, Horinouchi H, et al. Successful EGFR-TKI rechallenge of leptomeningeal carcinomatosis after gefitinib-induced interstitial lung disease. *Jpn J Clin Oncol*. 2013;43(4):422-425.
94. Lin CH, Lin MT, Kuo YW, et al. Afatinib combined with cetuximab for lung adenocarcinoma with leptomeningeal carcinomatosis. *Lung Cancer*. 2014;85(3):479-480.
95. James Chih-Hsin Yang, Dong-Wan Kim, Sang-We Kim, et al. Osimertinib activity in patients (pts) with leptomeningeal (LM) disease from non-small cell lung cancer (NSCLC): updated results from BLOOM, a phase I study. *J Clin Oncol*. 2016;34(suppl):9002.
96. Arrondeau J, Ammari S, Besse B, et al. LDK378 compassionate use for treating carcinomatous meningitis in an ALK translocated non-small-cell lung cancer. *J Thorac Oncol*. 2014;9(8):e62-e63.
97. Margolin K, Ernstoff MS, Hamid O, et al. Ipilimumab in patients with melanoma and brain metastases: an open-label, phase 2 trial. *Lancet Oncol*. 2012;13(5):459-465.
98. Di Giacomo AM, Ascierto PA, Pilla L, et al. Ipilimumab and fotemustine in patients with advanced melanoma (NIBIT-M1): an open-label, single-arm phase 2 trial. *Lancet Oncol*. 2012;13(9):879-886.
99. Fennira F, Pagès C, Schneider P, et al. Vemurafenib in the French temporary authorization for use metastatic melanoma cohort: a single-centre trial. *Melanoma Res*. 2014;24(1):75-82.
100. Long GV, Trefzer U, Davies MA, et al. Dabrafenib in patients with Val600Glu or Val600Lys BRAF-mutant melanoma metastatic to the brain (BREAK-MB): a multicentre, open-label, phase 2 trial. *Lancet Oncol*. 2012;13(11):1087-1095.
101. Azer MWF, Menzies AM, Haydu LE, et al. Patterns of response and progression in patients with BRAF-mutant melanoma metastatic to the brain who were treated with dabrafenib. *Cancer*. 2014;120(4):530-536.
102. Simeone E, De Maio E, Sandomenico F, et al. Neoplastic leptomeningitis presenting in a melanoma patient treated with dabrafenib (a V600EBRAF inhibitor): a case report. *J Med Case Reports*. 2012;6:131.
103. Poplack D, Bleyer WA, Horowitz M. *Pharmacology of Antineoplastic Agents in Cerebrospinal Fluid*. New York: Plenum Press; 1980.
104. Kim DY, Lee KW, Yun T, et al. Comparison of intrathecal chemotherapy for leptomeningeal carcinomatosis of a solid tumor: methotrexate alone versus methotrexate in combination with cytosine arabinoside and hydrocortisone. *Jpn J Clin Oncol*. 2003;33(12):608-612.
105. Zagouri F, Sergentanis TN, Bartsch R, et al. Intrathecal administration of trastuzumab for the treatment of meningeal carcinomatosis in HER2-positive metastatic breast cancer: a systematic review and pooled analysis. *Breast Cancer Res Treat*. 2013;139(1):13-22.
106. Hollebecque A, Levy A, Broutin S, et al. First case report of intrathecal panitumumab for treatment of meningeal carcinomatosis in an EGFR mutant lung adenocarcinoma patient. *Lung Cancer*. 2013;80(1):113-114.